

Blunt Trauma Abdomen, Pleural Effusion and Desaturation

Naresh G. Tirpude*, Vrishali Ankalwar**, Ramesh N. Sugandh***, Jyoti Naitam****

Abstract

In trauma cases, blunt trauma abdomen may be associated with head injury. Patient may die due to intra-abdominal bleeding. There may be minute diaphragmatic tear that may be undetected in USG. In absence of pneumo-thorax patient may develop life threatening pleural effusion (non- pathological) due to pressure gradient between intra - abdominal cavity & pleural cavity. The lung collapse may develop due to pleural effusion. During conservative management of cases of blunt trauma abdomen, patient may succumb due to such type of complication. Timely intervention either by inter-costal drainage & under water seal technique or surgical exploration of abdomen & repair of diaphragmatic tear is important to save life of patient. In the present case, patient was survived by timely inter costal drainage tubing with under water seal.

Introduction

In high speed vehicular accidents, head injury, bony fractures and blunt trauma to abdomen with no obvious external bleeding is a common occurrence. In cases of no immediate surgical indication, patients are being hospitalized for observation to exclude surgical issues, head injury and subd- ural / extradural

hematoma. The patients are managed conservatively for 24 hours to 48 hours.

The injury to soft tissues and abdominal organs can be diagnosed with the USG abdomen. The diagnosis of minute diaphragmatic tear may be missed when there is no herniation of bowel loops/ intestine into pleural cavity/ thorax. The intestinal/ bowel herniation is possible only when the rent in the diaphragm is large enough to allow intestines to enter the pleural cavity/ diaphragm.

The minute/small diaphragmatic tear of right side is difficult to diagnose as herniation of bowel is not a common feature. The herniation on right side of thorax is not common due to obstacle of liver. Patient may manifest clinically as pleural effusion/ haemo pneumo-thorax or hydro pneumothorax after 24 to 48 hours.

Many times surgeon focuses on Head injury and organ injury e.g., Liver, Spleen, Kidney, Uterus, Bladder etc.

A Case Report

A Girl child of 11 years old was admitted to the tertiary care hospital with the diagnosis of Blunt trauma abdomen. While travelling, she met with a motor vehicle accident (Bus). On admission clinically she had some minor abrasions over the

body with no other findings e.g., unconsciousness, bleeding, fractures, guarding of abdomen etc.

Findings/ status of patient on admission

- Patient's General condition: Conscious, well oriented in time and space.
- Pulse rate: 100/ min Regular.
- Blood Pressure: 90/ 60 mm/Hg
- Respiratory rate: 20/ min.
- Respiratory system, CVS, Abdomen, CNS, Spine examination: NAD

Investigations

- X- Ray Chest PA View: NAD
- USG abdomen: NAD

Management: As there was no obvious surgical indication, the patient was admitted for observation and conservative management.

Author's Affiliations:

*Prof. and Head Anesthesia & Vice Dean **Associate Professor ***Assistant Professor ****Assistant Professor, Dept. of Anesthesiology, Govt. Medical College, Nagpur.

Corresponding Author:

Dr. Naresh Tirpude, Plot No.- 38, FF- 401, Dwarkamai Apartment, Wanjari Nagar, Nagpur- P.C. 440 003, Maharashtra

E-mail: ngtirpude@yahoo.co.in

Findings/status of patient at 24 - 48 hours

- Patient's General condition: Conscious, oriented in time and space
- C/o Breathlessness and Restlessness
- Pulse rate: 110/ min. Regular
- Blood Pressure: 86 mm/Hg systolic
- Respiratory Rate: 26-30/ min.

Investigations

- *X-Ray Chest PA view:* Pleural effusion (Right)
- *Past history:* No past history of medical illness/ Pulmonary TB

On physician's opinion, the pleural tapping was done under local infiltration anesthesia. The Pleural tapping was done twice at the surgical ward. The patient was still breathless and restless. The general condition of the patient was deteriorating. The Tachycardia was constant and worrying sign as far as general condition of patient was concerned.

Findings/status of patient at 72 hours

- Breathlessness and Restlessness
- Pulse Rate : 110-112/ min.
- Blood Pressure : 80 mm/ Hg
- Resp. Rate : 26-30/ min
- Check X-Ray Chest : Pleural effusion with collapse of Right lung

When Clinical presentation of trauma patient is history of Blunt trauma abdomen with (a) No Head injury, (b) No Hemoperitoneum, (c) No Bowel perforation and (d) No bowel Herniation into thorax, Surgeon's always plan conservative management. When patient is under observation, close clinical assessment (Daily morning evening round), reviewing the investigations and diagnosis is very important to know the prognosis. 2nd clinician's opinion plays a very important role to avoid monotonous thought of diagnosis and management.

On 4th day of admission, 3rd time pleural tapping was planned at Operation Theatre and was in progress at the operation room of operation theatre. The pleural tapping was performed twice in the ward. This 3rd pleural tapping was planned at operation theatre thinking that tapping was incomplete due to non cooperation by patient.

Findings/status of patient at 84 hours

- General condition : Poor ; Severe breathlessness
- Pulse rate : 120/ min reg.
- Blood Pressure : 86 mm/ Hg (Systolic B.P.)
- Resp. Rate : 30-36/ min.
- SpO₂ : 56% (Low SpO₂)

There was no plan for exploration of abdomen as surgeons have no thought of diaphragmatic tear. Considering the deteriorating condition of patient, alarming low SpO₂ (Desaturation) as patient was being monitored by anesthesia team, 'Senior Anesthesiologist' intervened the surgeon's plan of management. The pleural tapping was withheld; history, treatment and investigations till date were reviewed.

Review of patient management by Senior Anesthesiologist

- History of Blunt trauma abdomen
- No head injury ; No Haemoperitoneum; No guarding of abdomen
- No herniation of abdominal contents; No history of medical illness in past
- X-Ray Chest- Pleural effusion & Collapse Lung (Rt.)
- Pulse rate- 120-130 / min. reg.; SpO₂- 56% (Desaturation) with oxygen supplementation using ventimask (Patient was breathing spontaneously)

Senior Anesthesiologist informed the 'senior surgeon and team' that cause of Low SpO₂ (Desaturation) is 'Pleural effusion with Collapse of Right lung' secondary to 'Diagnosis- Diaphragmatic tear (Right side)'. The Herniation of bowel was not possible on right side due to liver as an obstacle. As patient's prognosis was bad, the surgeon was instructed not to do only simple pleural tap but to explore abdomen as suspicion of diaphragmatic tear (Right side) and to rule out any organ injury and Hemoperitoneum.

The surgeon team was reluctant to explore the abdomen; it was due to ego problem of surgeon as anesthetist was instructing / requesting surgeon to operate. After healthy discussion and considering pleural effusion and collapsed lung, the inter-costal drain was inserted under local infiltration anesthesia and connected to underwater seal bag. Within 20 minutes, pleural fluid 300 ml was drained into the collecting bag.

Prognosis after Inter-costal Drain

- Breathlessness and restlessness was immediately reduced
- Pulse rate : 100/ min. regular (Decreased)
- Blood Pressure : 90-100 mm/ Hg (Improved)
- Respiratory rate : 24-26/ min (Decreased)
- SpO₂ : 56-60% to 90-94% (Dramatically Improved)

The tapped pleural fluid was slightly blood tinged. The Pleural fluid was sent for laboratory examination and report of pleural fluid was inconclusive. It was not positive for tuberculosis. Patient was kept under close observation at post anesthesia care unit. The concerned surgeon was instructed to explore the patient, if deteriorates. The later post-operative prognosis of patient was good and uneventful. There was no more pleural effusion or excess collection of fluid in the collecting bag in the postoperative period. The patient was not being explored for laparotomy / thoracotomy. She was survived and discharged after 15 days of hospitalization.

Discussion

The diagnosis of minute diaphragmatic tear is difficult till herniation/ pleural effusion. The clinical presentation of patient is as breathlessness and restlessness, tachycardia is due to uneven ventilation; sympathetic response to retained CO₂. When there is a rent in the pleural cavity/ thorax which is communicating externally to atmosphere or stability/ integrity of thoracic cage is destroyed/ disturbed either by trauma or by thoracic surgical interventions (multiple rib fractures due to trauma/ compression injury to chest), the abnormal movements of thorax and underlying lung may occur.

There are 3 principle conditions that must be considered:

- *Mediastinal flap*: When pleural cavity is open to atmosphere, lung collapses and pleural pressure becomes atmospheric of that side. During inspiration, there is a negative intra-pleural pressure on unaffected side leads to maximum pulling of heart and great vessels in to mediastinum towards sound lung. On expiration, the intra pleural pressure becomes less negative and mediastinum returns back to its original position. Consequences: It is dangerous in lateral position, as whole weight of mediastinal contents is compressing

dependent lung. It interferes with the refilling of great vessels, leading to decreased cardiac output.

- *Pendeluft*: It signifies pendulum like movement of air that occurs from one lung to opposite lung and vice versa in presence of an open pneumothorax and patient breathes spontaneously. During inspiration, lung on normal side fills with air partly from trachea and partly from partially deflated lung on the affected side. This is due to loss of intra-pleural pressure. On expiration the converse phenomena takes place and some expired air from normal lung passes over to other non-affected side lung. The consequences of pendelluft are re-breathing **increases and alveolar CO₂ tension increase.**
- *Paradoxical Respiration*: Due to crush injury of chest/ surgical removal of part of rib cage, the affected chest wall collapses. On inspiration the unaffected side will expand in normal fashion but injured side of thorax section will be sucked in. On expiration reverse movement takes place. It is seen in patient breathing spontaneously and abolished by controlled ventilation. It is an indication for artificial ventilation.

These abnormal chest/ thorax movements are only during the spontaneous breathing by the patient. All abnormal chest and lung movements are possible and patient's life is in danger when patient is breathing spontaneously. Irrespective of type of surgery, thoracic/ non thoracic controlled ventilation/ IPPV is important with inter-costal drainage tube and under water seal in situ.

The patients of Chest trauma have to face three evolving injuries

1. Injury to tissues themselves.
2. Due to effect of impaired ventilation, oxygen supply to meet increased metabolic demands after trauma cannot be met.
3. patient can enter into a negative cycle where ventilatory efforts becomes further uncoupled or ineffective due to hypoxia and acidosis, exacerbating all other injuries leading to tachycardia, sweating, hypotension, pleural effusion etc.

The clinical presentation of patient is in the form of sweating, breathlessness, restlessness, dysnoea, tachycardia, and hypotension. Similarly when there is trauma to chest with diaphragmatic tear (minute/ large) but no communication to external atmosphere;

during spontaneous respiration, there is uneven ventilation due to loss of integrity of thoracic movement. Herniation of intestines is not a common presentation as liver acts as an obstacle on right side.

The minute diaphragmatic tear may be missed in USG/ X- Ray chest. Conservative management may be fatal as patient condition may deteriorate due to progressive pleural effusion. In Anticipation that 'Exploratory laparotomy' may turn negative; early exploration of abdomen is very important.

Pleural Fluid composition

- Minute amount : 0.01 ml/ kg/ hour
- Normal cell : 1500 cell/ mm³
- Monocytes : 70- 80 %
- Mesothelial : 09 %
- Macrophages : 07-09 %
- PNLs : 02%

Pleural fluid contains small amount of proteins with abundant low mol. wt. protein (albumin).

Parameters	Pleural/ Fluid	Serum/ Plasma
HCO ₃	25> more	22- 28 meq./ lit
Sodium	3-5> more	135-145 meq./ lit
Chloride	6-9> more	--
K	equal	equal
Glucose	equal	equal

Ionic contents of Pleural fluid

Path physiology of Pleural Effusion

If Pleural fluid formation is > Capacity to absorb fluid by lymphatic system

(1) *Increased formation*

- Increased interstitial fluid in the lungs
- Increased intravascular pressures in pleura
- Increased pleural fluid protein level

(2) *Decreased absorption*

- Lymphatic obstruction of parietal pleura
- Diseased lymph nodes
- Increased systemic vascular pressure

(3) *Decreased pleural pressure*

- Diaphragmatic tear/ rupture
- Increased fluid in peritoneal cavity
- Rupture of thoracic duct/ blood vessel

Pleural fluid formation

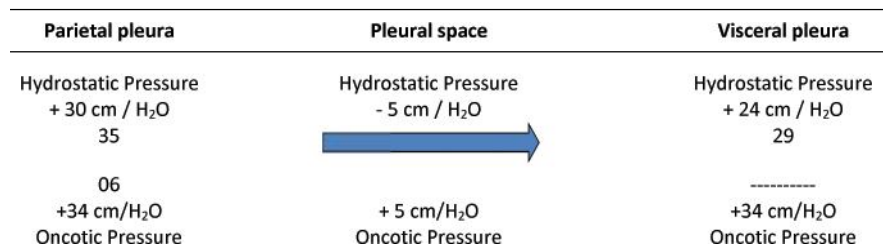
1. *Capillaries origin*

Other causes

2. *Interstitial origin:* Patients with heart failure

3. *Peritoneal cavity:* via hiatus/ tear in the diaphragm because of

- a. Pressure gradient across pleural & peritoneal cavity
- b. Hepato-hydro thorax 6-10%; Malignancy



c. Peritoneal dialysis; Meig's syndrome

4. Thoracic duct/blood vessel disruption:

In blunt trauma abdomen, fluid moves from abdomen to pleural cavity via diaphragmatic defect/ tear due to negative pressure gradient in pleural cavity (It is due to pressure gradient between / across abdomen and Pleural cavity).

Conclusion

Primary assessment

The Purpose of primary survey is rapid targeted assessment of airway, breathing and circulation to identify those injuries that must be corrected immediately to prevent rapid death. Airway,

breathing and circulation are assessed with the patient usually in supine position with cervical spine control and adequate exposure. During rapid and systematic primary survey.

Conditions to look for:

- Tension pneumothorax
- Open pneumothorax
- Flail chest
- Massive haemothorax
- Cardiac tamponade

Secondary survey to look for:

- Diaphragmatic rupture
- Rib fractures and flail segment
- Lung contusion
- Cardiac contusion
- Blunt aortic injury
- Oesophageal injury

Inspection

One should note signs of cyanosis, depth and rate of breathing, use of accessory muscles, tracheal tugging, dilated neck veins, obvious wounds, penetration points, open fractures, abrasions, bruising with deceleration injury/blunt trauma. Don't forget to examine the posterior chest wall. Are breath sounds present and normal? Are breath sounds present throughout both lung fields? Pulse oximetry and CXR are adjuncts to assessment. The clinician should act to treat immediate threat to patient.

In the present case, age of patient was 11 years. There was a history of high speed vehicle accident and blunt trauma to abdomen. There was no herniation of bowel loops / intestines as liver acts as an obstacle on the right side. The USG and X ray chest did not reveal minute tear of diaphragm. X-Ray chest revealed the pleural effusion which was progressive and lead to collapse of right lung.

In operation room, the Low SpO₂ (Desaturation-pulse oximetry monitoring) initiated the revision of/ rethinking of diagnosis of the patient. After intercostal drainage of pleural fluid, the SpO₂- 56% improved to 95%. Though there was no abdominal organ injury, patient would have fatal event due to pleural effusion. The negative exploratory

laparotomy may be accepted to rule out organ injury and bleeding in abdomen. There was no abdominal organ injury/ head injury. The minute diaphragmatic tear might have healed and hence there was no mortality in the present case.

References

1. Diaphragmatic hernia masquerading as pleural effusion. "12:42 EDT 10th April 2014 BioPortfolio.
2. Diaphragmatic hernia & Pleural effusion; Niger J Surg. 2012 Jul Dec; 18(2): 94-96. Z Nalladaru and A Wessels.
3. Chronic traumatic diaphragmatic hernia: the significance of pleural effusion. ; Aronchick JM1, Epstein DM, Gefter. Radiology.1988 Sep; 168(3): 675.
4. Right diaphragmatic hernia secondary to trauma- With Report of Two Cases Newell E. Wood and Francis L. Stutzman Calif Med. Nov 1959; 91(5): 251-254.
5. Bloody Pleural Effusion as a Complication of Hiatal Hernia- Muhammad Siddique, MD; Jonaid Aslam, MD; Mohammad Syed, MD; Misbat Chaudry, MD; Joseph Henkle, MD Chest. 2011; 140.
6. Delayed Presentation of Traumatic Diaphragmatic Hernia: a Diagnosis of Suspicion with Increased Morbidity and Mortality; Farooq Ahmad Ganie 1, * ; Hafeezulla Lone 1 ;Trauma Monthly. 2013 June; 18(1): 12-6.
7. Cases Journal- A case report- asymptomatic massive left sided pleural effusion with left lung collapse secondary to traumatic diaphragmatic hernia. Large pleural effusions are usually symptomatic. journal. Com / content/2/1/29.
8. Hepatothorax after right-sided diaphragmatic rupture mimicking a pleural effusion: a case report; Franz Georg Bader1*, Martin Hoffmann1, Tilman Laubert- Cases Journal 2009; 2: 8545.
9. Injury to the diaphragm: Our experience in Union Head quarters Hospital. 2013; 3 (4): 256-261 ; Angeline Neetha Radjou1, Dillip Kumar Balliga2, Muthandavan.